

S. INOKUCHI - N. USAMI

JUVENILE PLANTAR FIBROMATOSIS IN JAPAN.  
A CASE REPORT

*Estratto da:*

FOOT DISEASES

VOL. II - N. 2/1995



AULO GAGGI EDITORE  
BOLOGNA

# Juvenile Plantar Fibromatosis in Japan. A case report

S. Inokuchi - N. Usami

*Department of Orthopaedic Surgery School of Medicine, Keio University, Tokyo, Japan.*

**ABSTRACT: Juvenile plantar fibromatosis is very rare in Japan as well as in Europe. We report a case of a nine-year-old Japanese boy. Dupuytren's disease, which has a similar pathological change in palm to plantar fibromatosis, is rarer in Japan than in Europe. Plantar fibromatosis is also rarer in Japan than in Europe. In spite of this, Juvenile plantar fibromatosis is equally rare in both Japanese and Europeans. Considering the rate of complication of Dupuytren's disease in palms and plantar fibromatosis in the contralateral foot, and the influence of race, the pathogenesis may differ between children and adults.**

**KEY WORDS: Juvenile, plantar fibromatosis, Dupuytren's disease, Japanese.**

## INTRODUCTION

Plantar fibromatosis is much less common than palmar fibromatosis and is even rarer in children. We report a case of juvenile plantar fibromatosis and compare this disease between adults and children and between Japanese and Europeans.

## CASE REPORT

In March, 1992, a nine year-old-boy in good general health was seen for the excision of a slow growing painful nodule on his right sole. He had no history of trauma or inflammation of the sole. The lesion had become large enough to be noticed when he was four years old. Pain was absent in the beginning, but began while walking two years after the lesion was first noticed. Only a biopsy of the nodule was performed and the lesion

was diagnosed as leiomyoma. The nodule continued to grow slowly but steadily and the pain made it difficult to walk.

Examination revealed a 3 x 2 cm elastic soft tissue tumour on the medial side of the sole and the lesion was tender. There were no signs of inflammation i.e., redness, swelling or edema. The tumour was not adherent to the skin of the sole but fixed to the medial portion of the aponeurosis. There were no contractures nor range of motion limitation in the foot and ankle joints. There were no tumours on the contralateral sole or on either palm. Xerography showed a tumour-like lesion under the metatarsus (Fig. 1), which was not visible on a routine X-ray. The lesion had a low signal intensity area in both T1- and T2-enhanced MRI images (Fig. 2).

The tumour originated in the medial part of the plantar aponeurosis and was restricted to the middle of the fascia (Fig. 3). The tumour had not invaded either the lateral portion of the fascia or any muscle tissue. In September, 1992, surgery was performed making a zig-zag incision in the sole. The tumour was resected with the surrounding aponeurosis and

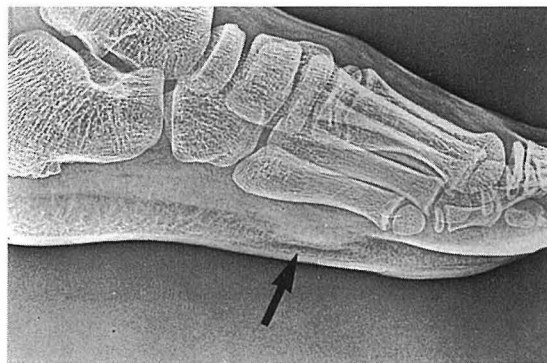

Fig. 1 - Xerography.

Table I  
CASES OF THE JUVENILE PLANTAR FIBROMATOSIS

			age	sex	side
1	Keasbey	1953	9Y	Female	Right
2	Arthur	1954	at birth	Male	Unilateral
3			at birth	Female	Unilateral
4			12Y(?)	Female	Unilateral
5			Allen	1956	3Y
6	Karl	1985	2Y	Male	Right
7			2Y	Male	Right
8			2Y	Male	Left
9	Abdul	1989	13Y	Female	Right
10	Nishinou	1969	7M	Female	Right
11	Honnma	1974	2Y	Female	Left
12	Morimoto	1985	9Y	Male	Right
13	Matsumura	1992	6Y	Male	Left
14	Authors	1994	4Y	Male	Right

the skin could be closed without a local or remote skin flap.

Pathologically, fibroblasts and collagen fibres had proliferated in the tendinous tissue of the aponeurosis (Fig. 4). There were no malignant findings such as mitotic figures or cellular atypia. The lesion was diagnosed as plantar fibromatosis based on the clinical and pathological findings. There has been no more pain or interference with daily life or tendency to recur up to now, two years after the operation.

## DISCUSSION

Plantar fibromatosis is characterized by benign proliferation of well differentiated fibroblastic tissue in the plantar fascia. It is similar to Dupuytren's contracture, palmar fibromatosis, but much less severe.

Like Dupuytren's contracture, plantar fibromatosis is less common in Japan than in Europe. Only forty-eight cases have been reported in Japan. Plantar fibromatosis is also rarer in children than in adults in Japan and

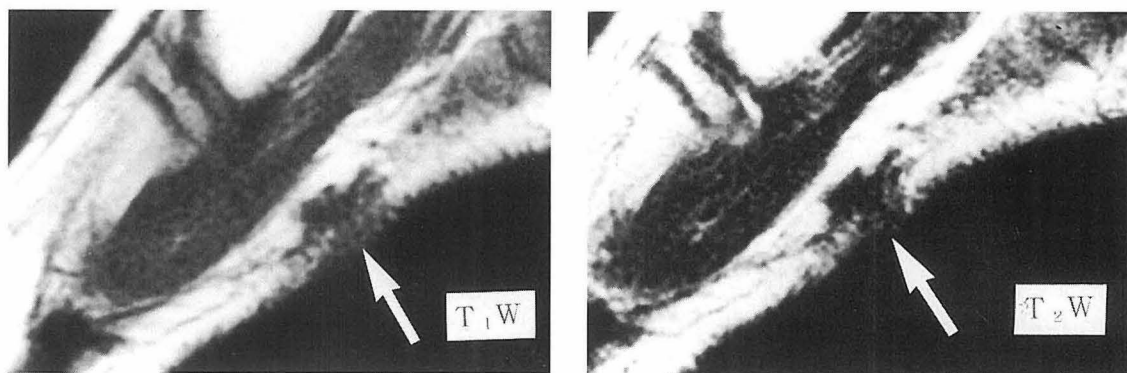
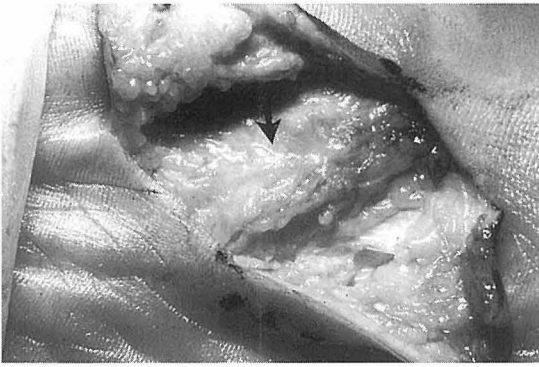


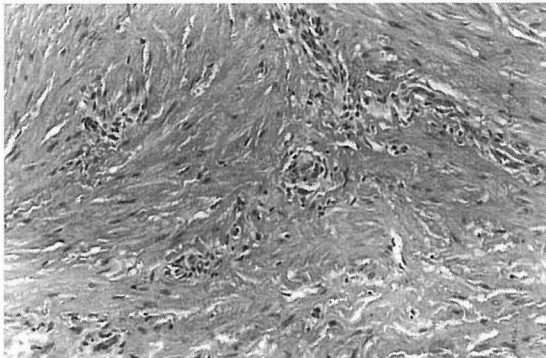
Fig. 2 - Low signal intensity area in both T1 - (A) and T2 - (B) enhanced MRI images.



**Fig. 3** - Tumor originated in the medial part of the plantar aponeurosis.

only five cases under the age of sixteen, including this one, were found in the literature<sup>1,2,3,4</sup> (Table I). According to gender, the children included three males and two females, while the ratio in adults of males to females is 3 to 1. The age at onset in Japan ranged from seven months to nine years, averaging 4.4 years in children versus 49.8 years in Japan. Three cases involved the right foot and two cases the left foot. There have been no bilateral cases in children, whereas bilateral cases have accounted for more than one third of adult cases. In Japan, palmar fibromatosis occurred as a complication in almost half of the adult cases, while it did not occur in any of the children.

The tumour grew slowly and the clinical course was protracted in both children and



**Fig. 4** - fibroblasts and collagen fibres proliferated in the tendinous tissue of the aponeurosis.

adults.

Pathologically, plantar fibromatosis in children may range from Enneking stage I to stage III, the same as in adults.

Simple tumour excision was performed in two of the five children and the lesion recurred in both cases. No recurrences have been observed after simple excision in adults. Partial fasciectomy was performed in three children and the tumour recurred in only one. In two out of six adults treated in the same way there were recurrences. On the whole, recurrence tends to be more frequent in children, but after partial fasciectomy, the rate of recurrence is almost the same. Many authors began to advocate wide resection because of the high recurrence rate after simple resection. We performed partial fasciectomy since the lesion was stage I and the plantar fascia has an important function in winding up the arch of the foot during walking. Whether partial or wide resection should be performed depends on the pathological stage.

We found only nine cases of juvenile plantar fibromatosis reported outside Japan<sup>5,6,7</sup>. Juvenile plantar fibromatosis may be rare in European countries as in Japan, but the incidence of palmar fibromatosis is higher in Europe than in Japan. The peak age at onset, gender distribution, left or right foot involvement, complications and recurrence rate are similar in both Japanese and European children.

## CONCLUSION

We have reported a rare case of juvenile plantar fibromatosis which has no preference to race. However, the incidence of Dupuytren's contracture is lower in Japanese than in Europeans.

## REFERENCES

1. NISHINO H., HIGUCHI M.: A case report of plantar fibromatosis. *Tyubuseisaischi*, **12**:900, 1969.
2. HONMA M.: Palmar fibromatosis and plantar fibromatosis. *Nippikaishi*, **84**:311, 1974.

3. MORIMOTO K., et al.: A case report plantar fibromatosis with infiltration from foot sole to dorsum. *Seikeigeka*, **36**:1719-1723, 1985.
4. MATSUMURA H., et al.: A study of plantar fibromatosis with special reference to four isolated plantar fibromatosis cases. *Keiseigeka*, **35**:71-77, 1992.
5. KEASBEY L.E.: Juvenile aponeurotic fibroma (calcifying fibroma). A distinctive tumor arising in the palms and soles of young children. *Cancer*, **6**:338-346, 1953.
6. ALLEN A.R., et al.: Soft tissue tumors of the sole. *J. Bone Joint Surg.*, **37-A**:14-21, 1955.
7. KARL T.K., CHEN TIMOTHY A. VAN DYNE: Familial plantar fibromatosis. *J. Surg. Oncol.*, **29**:240-241, 1985.